

Fast Assessment of Acetabular Coverage using Stereoscopic Volume Rendering

Jiro Inoue¹, Marta Kersten¹, Burton Ma¹, James Stewart¹, John Rudan², Randy Ellis^{1,2,3}

¹*School of Computing, Queen's University, Canada*

²*Department of Surgery, Queen's University, Canada*

³*Contact author: ellis@bwh.harvard.edu*

1 Background

Acetabular dysplasia is typically assessed by measuring the amount of acetabular coverage over the femoral head, but current 2D methods used to assess acetabular coverage are inaccurate due to the 3D nature of the local anatomy. Although there is currently no “gold standard” for measuring acetabular coverage in 3D, a number of CT-based approaches have been proposed in the literature [1, 2, 3], all of which are time-intensive.

The goal of this research was to develop a fast and accurate method of measuring acetabular coverage using digitally reconstructed radiographs (DRRs) and stereoscopic rendering.

2 Tools and Methods

DRRs were generated and displayed in real-time on a PC with a 2.8GHz Pentium 4 CPU, 1 GB of RAM, an nVidia Quadro FX1100 video card, and a ViewSonic Professional Series P95f+ CRT monitor. Wireless 3D glasses (eDimensional 3D Vision System) were used for stereoscopic visualization.

Our data consisted of pre-operative and post-operative CTs collected from five volunteers previously treated with computer-assisted periacetabular osteotomy (10 total data sets). The CTs were taken for the purposes of treatment by image-guided surgery, prior to the conception of our research. The subjects of the experiment were two graduate students with experience in processing CT data for computer-assisted orthopaedic surgeries.

The data were aligned in the CT coordinate frame and displayed as DRRs in a craniocaudal view. Both subjects picked the outlines of the acetabulum and femoral head in both monocular and stereoscopic rendering modes for each of the 10 data sets for a total of 40 tests. A DRR, with femoral and acetabular outlines, are shown in Figure 1.

3 Results

The average time for outlining the overlapping areas was 39 seconds for the monocular renderings, and 42 seconds for the stereoscopic ones. Because there is no “gold standard” for area-based acetabular coverage assessment, we compared our results to those of Mechlenberg *et al.* [2]. Two-way independent-sample t-tests showed that stereoscopic DRR based measurements correlated with the method of Mechlenberg ($t = -0.825$, $p = 0.415$), while the monocular DRR based measurements did not ($t = -2.148$, $p = 0.038$).

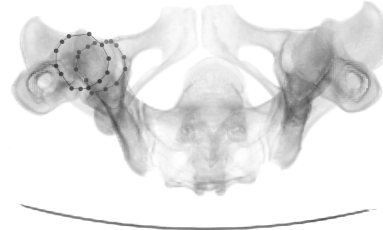


Figure 1: A craniocaudal DRR of the pelvis with outlined acetabulum and femoral head.

4 Conclusions/Discussions

The positive correlation of the stereoscopic measurements with the method of Mechlenberg *et al.* suggests that there is a benefit to using stereoscopic visualization, and that our method is an accurate method of measuring acetabular coverage. Furthermore, our method is fast, taking under a minute to perform.

Our method is capable of coverage area measurements similar to Klaue *et al.* [1] but with far fewer measurements and on a single image as opposed to approximately 20 images. Compared to Nakamura *et al.* [3], our method requires much less pre-processing of CTs. The method of Mechlenberg *et al.* also measures the same coverage area, but from a sagittal view, and requires visualizing many slices individually.

The next phase of this research will involve refinement of our system to allow streamlined testing and the recruitment of radiologist subjects to validate the accuracy of our method, followed by pilot clinical testing of this method in the context of computer-aided surgery.

References

- [1] K. Klaue, A. Wallin, and R. Ganz. CT evaluation of coverage and congruency of the hip prior to osteotomy. *Clin. Orth. Rel. Res.*, 232:15–25, 1988.
- [2] I. Mechlenburg, J. Nyengaard, L. Rømer, and K. Søballe. Changes in load-bearing area after Ganz periacetabular osteotomy evaluated by multislice CT scanning and stereology. *Acta Orth. Scand.*, 75(2):147–153, 2004.
- [3] S. Nakamura, J. Yorikawa, K. Otsuka, K. Takeshita, A. Harasawa, and T. Matsushita. Evaluation of acetabular dysplasia using a top view of the hip on three-dimensional CT. *J. Orth. Sci.*, 5:533–539, 2000.